



doi: [10.1016/j.jcrs.2004.02.052](https://doi.org/10.1016/j.jcrs.2004.02.052) [? Cite or Link Using DOI](#)
 Copyright © 2004 ASCRS and ESCRS. Published by Elsevier Inc.

Article

Clinical course of severe central epithelial defects in laser in situ keratomileusis*¹

Alireza Mirshahi MD^{a, b}, Jens Bühren MD^a and Thomas Kohnen MD^{a, b}    

^a Department of Ophthalmology, Johann Wolfgang Goethe-University, Frankfurt am Main, Germany

^b Recklinghausen Eye Center, Recklinghausen, Germany

Accepted 11 December 2003. Available online 13 August 2004.

Abstract

Purpose: To report the clinical outcome of laser in situ keratomileusis (LASIK) cases complicated by severe central intraoperative epithelial defects (EDs) caused by the microkeratome cut.

Setting: Department of Ophthalmology, Johann Wolfgang Goethe-University, Frankfurt am Main, Germany.

Methods: In a retrospective study of 1650 LASIK cases at 1 center, the preoperative data, surgical procedures, and postoperative course in 22 eyes of 14 patients who experienced severe central EDs during the LASIK procedure (1.3%) were reviewed. The surgery was performed using a Technolas® C-LASIK 217 excimer laser (Bausch & Lomb) and a Hansatome® microkeratome (Bausch & Lomb). A follow-up of at least 12 months was available in all but 1 case. The median follow-up was 13.5 months (range 12 to 25 months). In the postoperative period, the following parameters were reviewed: course of refraction, best spectacle-corrected visual acuity (BSCVA), slitlamp findings, and corneal topography.

Results: The mean patient age was 42 years (range 27 to 61 years). Eight patients were

This Document

- [SummaryPlus](#)
- ▶ [Full Text + Links](#)
 - [Full Size Images](#)
 - [PDF \(258 K\)](#)

External Links

- 

Actions

- [Cited By](#)
- [Save as Citation Alert](#)
- [E-mail Article](#)
- [Export Citation](#)

affected bilaterally. Fifteen eyes (68%) had moderate to severe dry-eye symptoms preoperatively. Almost all eyes lost BSCVA in the postoperative period, and visual acuity improved slowly. By the last follow-up visit, no eye had lost more than 1 line of BSCVA. Diffuse lamellar keratitis (DLK) was observed in 20 eyes (91%), irregular astigmatism in 17 (77%), and microfolds in 12 (55%). In unilaterally affected patients, the refractive outcome was better in the nonaffected eye.

Conclusions: A large central ED is a severe intraoperative complication of LASIK that may lead to DLK, irregular astigmatism, flap microfolds, clearly prolonged visual rehabilitation, and temporary loss of BSCVA. The improvement in BSCVA may take several months.

Article Outline

- [Patients and Methods](#)
 - [Results](#)
 - [Discussion](#)
 - [References](#)
-

Laser in situ keratomileusis (LASIK) is currently the most popular refractive surgery procedure worldwide. The range of available correction, reliability and safety of results, and speed of visual recovery made the procedure the most revolutionary breakthrough in ophthalmology in the 1990s. Technical development has made the microkeratome cut a safe procedure, which is followed by laser ablation of the cornea to achieve the refractive effect. [1] Intraoperative epithelial defects (EDs) are a common complication [2 and 3] that may be associated with epithelial ingrowth, [4 and 5] flap edema, diffuse lamellar keratitis (DLK), [6] overcorrection or undercorrection, [3] flap melting, [7] and haze. [8 and 9] However, these complications are observed in only a small percentage of EDs. [10 and 11] Large, particularly central, EDs are rare but of potential risk to vision since the optical axis and not the flap periphery is affected. Several risk factors, eg, age, corneal thickness, and skin type, are associated with an increased incidence of EDs. [2 and 3]

Since no comprehensive data have been published on the clinical outcome of LASIK cases complicated by large central EDs, this study was performed to report the clinical course of large central EDs caused by the microkeratome cut.

Patients and Methods

In this retrospective study, the records of 1650 LASIK procedures performed in the Department of Ophthalmology of the Johann Wolfgang Goethe-University between 1997 and 2001 to correct myopia, hyperopia, and astigmatism were reviewed. All surgery was performed by 1 of 2 experienced ophthalmic surgeons (T.K., G.S.). Only EDs larger than 1.5 mm² that affected the visual axis were included in the study. A uniform LASIK technique using the Hansatome® microkeratome (Bausch & Lomb) and the Technolas® C-LASIK 217 excimer laser (Bausch & Lomb) was performed during the study period.[12 and 13]

Postoperatively, all patients were treated with an antibiotic, a steroid, and artificial tears. The treatment duration and dose were modified individually depending on the clinical course. All patients were examined on day 1 and after 1 week and 1 month. When necessary, further appointments were made to observe the visual performance. Beside demographics, the following parameters were reviewed in the follow-up examinations: preoperatively—subjective manifest refraction, best spectacle-corrected visual acuity (BSCVA), corneal topography (Orbscan®, Bausch & Lomb), severity of dry-eye syndrome, and biomicroscopy of the anterior segment. Postoperatively—course of subjective manifest refraction and BSCVA, course of corneal topography change (including assessment of central corneal irregular astigmatism), time and outcome of retreatments, and biomicroscopy of the anterior segment. In cases with only 1 affected eye, the refractive outcome was compared to that in the fellow eye (6 cases).

The assessment of irregular astigmatism was done using the irregularity index of the Orbscan corneal topography for the central 3.0 mm zone; this compares the measured area to a best-fit aconic sphere at the central region.

Microsoft Excel® and SPSS (version 10.0.7) were used for data collection and statistical analysis. A *P* value less than 0.05 was considered statistically significant. Data accumulation conformed with all local and state laws.

Results

Twenty-two eyes (14 patients) (incidence 1.3%) in which severe central EDs had occurred during surgery were identified. The mean age of the 6 women and 8 men was 42 years (range 27 to 61 years). All cases completed a minimum follow-up period of 12 months, except 1 hyperopic patient (2 eyes) whose data are presented as a single case. The median follow-up period was 13.5 months (mean 14.6 months; range 12 to 25 months).

Eight patients had bilateral central EDs (Figure 1). None of the surgery was performed simultaneously. All patients were myopic or myopic astigmatic except 1 (2 eyes), who did not meet the criterion of at least 12 months of follow-up. Since this patient had hyperopic astigmatism, the refractive development of BSCVA is reported as a single case. In 16 eyes (72.7%), the surgeon used a bandage contact lens immediately after the surgery was completed.

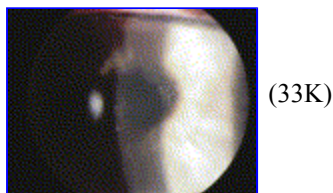


Figure 1. (Mirshahi) Slitlamp image of a severe central ED caused by the microkeratome cut.

Preoperatively, 15 eyes (68.2%) had moderate to serious dry-eye symptoms (Schirmer test). Basal membrane dystrophy, cornea guttata, and mild subepithelial opacification were seen in

1 patient (both eyes) each during the slitlamp examination.

The course of the BSCVA (logMAR) and the spherical equivalent (SE) are shown in [Figure 2](#) and [Figure 3](#), respectively. Seventeen cases (almost 80%) had postoperative irregular astigmatism on corneal topography maps; this became milder over time ([Figure 4](#) and [Figure 5](#)). While 4 (21.1%) of the 19 eyes achieved the preoperative BSCVA scores in the mid-term follow-up examination (4 to 8 months after the initial surgery), 3 others (15.8%) lost 2 or more lines of Snellen visual acuity. In the last follow-up examination, 12 (60%) of the 20 eyes achieved the original visual acuity; none lost more than 1 line of Snellen. In 1 case, there was an improvement of 1 Snellen line.

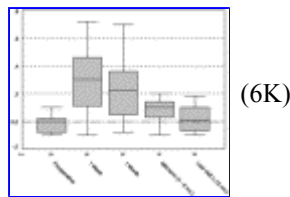


Figure 2. (Mirshahi) The course of the BSCVA (logMAR). The boxes show the median, 50% quartile, minimum, and maximum.

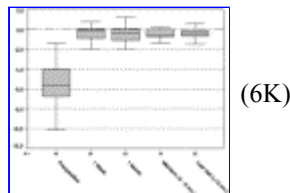


Figure 3. (Mirshahi) Development of refraction (SE, D). The boxes show the median, 50% quartile, minimum, and maximum.

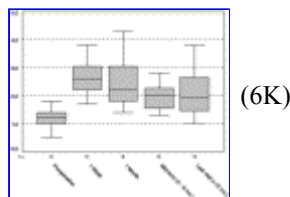


Figure 4. (Mirshahi) Development of irregularity on the corneal topography (irregularity index, D). The boxes show the median, 50% quartile, minimum, and maximum.

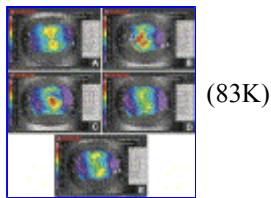


Figure 5. (Mirshahi) Development of corneal topography after LASIK complicated by a severe central ED (Orbscan, tangential keratometric map). *A*: Preoperative scan. *B*: 1 week after LASIK. *C*: At 1 month. *D*: At 2 months. *E*: At 5 months. Note the decrease in irregular astigmatism over time.

During the early postoperative period, diffuse lamellar keratitis (DLK) stage I–II developed in 20 eyes (90.9%). Treatment with topical steroids was intensified and prolonged in these patients. Six eyes (27.3%) developed paracentral epithelial islands in the interface during the follow-up, and peripheral epithelial ingrowth was observed in an additional 5 eyes (22.7%). In 1 eye, surgery to remove the epithelial growth from the interface was necessary. Laser in situ keratomileusis retreatment was necessary in 5 eyes to correct residual refractive errors. No refinement procedure was performed earlier than 4 months after the initial surgery. At the final follow-up, the slitlamp examination revealed interface haze/snowflakes in 2 eyes (9.1%), microfolds in 12 (54.5%), map-dot-fingerprint dystrophy signs in 6 (27.3%; observed preoperatively in 2 eyes), epithelial irregularity in 2 (9.1%), mud cracks and iron deposit in 1 eye each (4.5%), and mild subepithelial opacification or cornea guttata in both eyes of 2 patients (observed preoperatively). One patient developed recurrent paracentral EDs (corneal erosions) with concomitant DLK in both eyes during the 15-month follow-up. No corneal abnormality except mild dry-eye syndrome was noticed in this case preoperatively.

The refractive outcome in the affected eyes (Group 1) and nonaffected eyes (Group 2) of patients who experienced EDs unilaterally (6) was as follows: One month after surgery, 4 eyes in Group 1 were within ± 1.0 diopter (D) of emmetropia and 3 were within ± 0.5 D. In Group 2, all eyes were within ± 1.0 D of emmetropia and 4 were within ± 0.5 D (all SE). Two Group 1 ED eyes and no Group 2 eye had LASIK retreatment. The mean SE was -0.33 D (median 0.13 D) in the ED group and -0.06 D (median 0.13) in the uneventful surgery group.

The course of refraction and visual acuity in the hyperopic patient (both eyes) was as follows: The refraction was $+3.75 -3.5 \times 100$ in the right eye and $+3.75 -2.75 \times 85$ in the left eye preoperatively; $+0.25 -1.00 \times 90$ and $-0.25 -0.50 \times 74$, respectively, at 1 month; and $+0.25 -1.00 \times 15$ and $-0.50 -0.75 \times 170$, respectively, at 7 months. The BSCVA (logMAR) was -0.04 in the right eye and -0.08 in the left eye preoperatively; 0.16 and 0.0, respectively, at 1 month; and 0.24 and 0.06, respectively, at 7 months. Laser in situ keratomileusis retreatment was performed in the patient's right eye after the 7-month visit, but the patient did not appear for monitoring after the refinement procedure, although she stated that she was happy with the outcome.

Discussion

Our results demonstrate that large central EDs stunt visual restoration after LASIK. Refractive and especially visual acuity development are markedly prolonged. The restoration of BSCVA in our study took several months. Although there was a significant loss of visual acuity in about 80% of cases at the mid-term examination (4 to 8 months postoperatively),

the visual acuity loss was observed in only 30% of cases at the last examination, performed at least 1 year after the initial procedure, with no affected eye losing more than 1 Snellen line of BSCVA. Similarly, the refractive results seemed to be negatively influenced by central EDs, as the intraindividual comparison in the unilaterally affected patients and the relatively high number of retreatments (6 cases, 27.3%) suggest. Although the number of unilateral events in our study was too small to be conclusive, our results agree with those in the retrospective study of 1436 LASIK cases by Mulhern and coauthors,[14] which demonstrates that eyes affected by interface keratitis and EDs have a larger deviation from emmetropia than eyes with interface keratitis alone.

The appearance of DLK in the early postoperative course in more than 90% of cases is another important outcome of our study and clearly demonstrates the association between EDs and abnormal wound healing. Although this relationship has been described by others,[6 and 11] the level of the association found in our study is impressive and suggests that large central EDs might have a greater influence on corneal wound healing than mild peripheral defects. Since DLK, which is characterized by invasion of inflammatory cells into the LASIK interface, [11 and 15] occurred in all our cases despite regular postoperative treatment with topical steroids and since the steroids are known to reduce the intensity and duration of the inflammatory response, we conclude that not treating with steroids, which might be considered because of the break in the epithelium integrity, might have led to higher grades of DLK and resulted in severe loss of BSCVA. Therefore, we recommend instilling steroid drops in cases of EDs and, most important, observing the course regularly and meticulously.

Recently, cases of diffuse haze following epithelial abrasion for the treatment of flap folds have been reported.[8 and 9] Bühren and Kohnen[9] report a case of DLK, grade 2 haze, and temporary myopic shift of 2.0 D following epithelial debridement. Confocal microscopic examination revealed a significantly altered wound-healing reaction due to keratocyte apoptosis in the underlying stroma and consecutive stromal repopulation, which appeared clinically as haze and myopic shift. A partial effect on the cornea (eg, 1 large defect in the lower hemisphere) will result in irregular astigmatism from locally altered wound healing. In fact, 1 month after the surgery, irregular astigmatism and a negative SE were seen in 17 eyes (77.3%) and 18 eyes (81.8%), respectively, in the present series.

Slitlamp findings in our series suggest that development of microfolds is associated with intraoperative EDs. Microfolds rarely affect the visual acuity, especially if the visual axis is not involved.[11] It has been shown that patients with basal membrane dystrophy have poorly adherent epithelium and are predisposed to EDs during the microkeratome cut. [16] Thus, we hypothesize that some of our patients might have had basement membrane dystrophies that were almost unremarkable clinically. A pathogenetic link to the frequent occurrence of microfolds, which may appear as wrinkles in Bowman's layer or in the epithelial basal membrane, [17 and 18] seems probable. A high incidence of epithelial ingrowth during the postoperative course, as observed in our study, agrees with the finding of other authors, [4 and 5] who report a statistically significant correlation between EDs during surgery and epithelial ingrowth. A possible explanation for this phenomenon is that EDs induce high epithelial proliferation, leading to cell migration under the flap edge. As shown in our study, other rare postoperative findings, eg, interface haze, might be associated with intraoperative EDs.

We observed a case of recurrent corneal erosions and DLK following a surgically induced ED that had initially healed. This rare complication of LASIK has been reported by only a

few authors.[19 and 20] Ti and Tan [20] report 5 cases of recurrent corneal erosions associated with EDs during LASIK, and they hypothesize that LASIK can trigger or precipitate recurrent corneal erosions. We believe the occurrence of large intraoperative EDs and postoperative recurrent corneal erosions are clinical appearances of the same disease: undiagnosed or subclinical basal membrane dystrophy.

We did not compare our results with those in an age- and refraction-matched population because we think fast visual restoration and stability of refraction in uneventful LASIK cases have been proved.[1 and 12] Therefore, comparison with a matched group of uncomplicated LASIK eyes would deliver results that are actually obvious to the clinicians.


Previous studies verify the likelihood that the second operated eye will develop an ED if the first eye does.[3] Our results corroborate this observation in that 8 of the 14 patients with large central EDs developed them bilaterally. Recent studies indicate the overall incidence of EDs with the Hansatome microkeratome is between 9.7% and 16%. [2 and 3] Furthermore, risk factors, eg, age and skin type, have been identified. [2 and 3] Epithelial defects occur when the shearing force from the microkeratome pass overwhelms the adhesion between the epithelium and the basement membrane. A modification of the Hansatome microkeratome by a rounded trailing edge of the plate (zero-compression head) appears to significantly reduce EDs in LASIK, [21] potentially reducing the future incidence of large central EDs. As our study shows that large central EDs are not benign complications, we consider knowledge of their clinical course to be valuable for clinicians.

References

1. A. Sugar, C.J. Rapuano, W.W. Culbertson *et al.*, Laser in situ keratomileusis for myopia and astigmatism: safety and efficacy. (Ophthalmic Technologies Assessment) A report by the American Academy of Ophthalmology. *Ophthalmology* **109** (2002), pp. 175–187. [SummaryPlus](#) | [Full Text + Links](#) | [PDF \(134 K\)](#)
2. M. Bashour, Risk factors for epithelial erosions in laser in situ keratomileusis. *J Cataract Refract Surg* **28** (2002), pp. 1780–1788. [SummaryPlus](#) | [Full Text + Links](#) | [PDF \(155 K\)](#)
3. N.H. Tekwani and D. Huang, Risk factors for intraoperative epithelial defect in laser in situ keratomileusis. *Am J Ophthalmol* **134** (2002), pp. 311–316. [SummaryPlus](#) | [Full Text + Links](#) | [PDF \(194 K\)](#)
4. N. Asano-Kato, I. Toda, Y. Hori-Komai *et al.*, Epithelial ingrowth after laser in situ keratomileusis: clinical features and possible mechanisms. *Am J Ophthalmol* **134** (2002), pp. 801–807. [SummaryPlus](#) | [Full Text + Links](#) | [PDF \(348 K\)](#)
5. M.Y. Wang and R.K. Maloney, Epithelial ingrowth after laser in situ keratomileusis. *Am J Ophthalmol* **129** (2000), pp. 746–751. [SummaryPlus](#) | [Full Text + Links](#) | [PDF \(701 K\)](#)
6. M.N. Shah, M. Misra, K.R. Wilhelmus and D.D. Koch, Diffuse lamellar keratitis associated with epithelial defects after laser in situ keratomileusis. *J Cataract Refract Surg* **26** (2000), pp. 1312–1318. [SummaryPlus](#) | [Full Text + Links](#) | [PDF \(577 K\)](#)
7. A. Castillo, D. Diaz-Valle, A.R. Gutierrez *et al.*, Peripheral melt of flap after laser in situ

- keratomileusis. *J Refract Surg* **14** (1998), pp. 61–63. [Abstract-EMBASE](#) | [Abstract-MEDLINE](#) | [Abstract-ScienceDirect Navigator](#) | [\\$Order Document](#)
8. I.C. Kuo, R. Ou and D.G. Hwang, Flap haze after epithelial debridement and flap hydration for treatment of post-laser in situ keratomileusis striae. *Cornea* **20** (2001), pp. 339–341. [Abstract-EMBASE](#) | [Abstract-MEDLINE](#) | [Abstract-ScienceDirect Navigator](#) | [\\$Order Document](#) | [Full Text via CrossRef](#)
9. J. Bühren and T. Kohnen, Corneal wound healing after laser in situ keratomileusis flap lift and epithelial abrasion. *J Cataract Refract Surg* **29** (2003), pp. 2007–2012. [SummaryPlus](#) | [Full Text + Links](#) | [PDF \(311 K\)](#)
10. R. Ambrosio, Jr and S.E. Wilson, Complications of laser in situ keratomileusis: etiology, prevention, and treatment. *J Refract Surg* **17** (2001), pp. 350–379. [Abstract-MEDLINE](#) | [\\$Order Document](#)
11. S.A. Melki and D.T. Azar, LASIK complications: etiology, management, and prevention. *Surv Ophthalmol* **46** (2001), pp. 95–116. [SummaryPlus](#) | [Full Text + Links](#) | [PDF \(641 K\)](#)
12. T. Kohnen, G.W.K. Steinkamp, E.-M. Schnitzler *et al.*, LASIK mit superiorem Hinge und Scanning-Spot-Excimerlaserablation zur Korrektur von Myopie und myopem Astigmatismus; Einjahresergebnisse einer prospektiven klinischen Studie an 100 Augen. *Ophthalmologe* **98** (2001), pp. 1044–1054. [Abstract-EMBASE](#) | [Abstract-MEDLINE](#) | [Abstract-ScienceDirect Navigator](#) | [\\$Order Document](#) | [Full Text via CrossRef](#)
13. T. Kohnen, A. Mirshahi, M. Cichocki *et al.*, Laser-in-situ-Keratomileusis zur Korrektur von Hyperopie und hyperopem Astigmatismus mit Scanning-Spot-Excimer-Laser; Einjahresergebnisse einer prospektiven klinischen Studie. *Ophthalmologe* **100** (2003), pp. 1071–1078. [Abstract-MEDLINE](#) | [Abstract-ScienceDirect Navigator](#) | [\\$Order Document](#) | [Full Text via CrossRef](#)
14. M.G. Mulhern, J. Naor and D.S. Rootman, The role of epithelial defects in intralamellar inflammation after laser in situ keratomileusis. *Can J Ophthalmol* **37** (2002), pp. 409–415. [Abstract-EMBASE](#) | [Abstract-MEDLINE](#) | [Abstract-ScienceDirect Navigator](#) | [Abstract-ScienceDirect Navigator](#) | [\\$Order Document](#)
15. J. Bühren, M. Baumeister, M. Cichocki and T. Kohnen, Confocal microscopic characteristics of stage 1 to 4 diffuse lamellar keratitis after laser in situ keratomileusis. *J Cataract Refract Surg* **28** (2002), pp. 1390–1400.
16. K.A. Dastgheib, T.E. Clinch, E.E. Manche *et al.*, Sloughing of corneal epithelium and wound healing complications associated with laser in situ keratomileusis in patients with epithelial basement membrane dystrophy. *Am J Ophthalmol* **130** (2000), pp. 297–303. [Abstract](#) | [PDF \(286 K\)](#)
17. M. Vesaluoma, J. Pérez-Santonja, W.M. Petroll *et al.*, Corneal stromal changes induced by myopic LASIK. *Invest Ophthalmol Vis Sci* **41** (2000), pp. 369–376 erratum, 2027. [Abstract-EMBASE](#) | [Abstract-Elsevier BIOBASE](#) | [Abstract-MEDLINE](#) | [Abstract-ScienceDirect Navigator](#) | [\\$Order Document](#)

18. J.S. Pannu, Wrinkled corneal flaps after LASIK. *J Refract Surg* **13** (1997), p. 341 [letter]. [Abstract-MEDLINE](#) | [Abstract-ScienceDirect Navigator](#) | [\\$Order Document](#)
19. W.W. Haw and E.E. Manche, Late onset diffuse lamellar keratitis associated with an epithelial defect in six eyes. *J Refract Surg* **16** (2000), pp. 744–748. [Abstract-EMBASE](#) | [Abstract-MEDLINE](#) | [Abstract-ScienceDirect Navigator](#) | [\\$Order Document](#)
20. S.-E. Ti and D.T.H. Tan, Recurrent corneal erosion after laser in situ keratomileusis. *Cornea* **20** (2001), pp. 156–158. [Abstract-EMBASE](#) | [Abstract-MEDLINE](#) | [Abstract-ScienceDirect Navigator](#) | [\\$Order Document](#) | [Full Text via CrossRef](#)
21. T. Kohnen, E. Terzi, A. Mirshahi and J. Bühren, Intraindividual comparison of epithelial defects during laser in situ keratomileusis using standard and zero-compression Hansatome microkeratome heads. *J Cataract Refract Surg* **30** (2004), pp. 123–126. [Abstract-EMBASE](#) | [Abstract-MEDLINE](#) | [Abstract-ScienceDirect Navigator](#) | [\\$Order Document](#)

 Corresponding author. Reprint requests to Thomas Kohnen, MD, Department of Ophthalmology, Johann Wolfgang Goethe-University, Theodor-Stern-Kai 7, 60590 Frankfurt am Main, , Germany.

*1 Dr. Kohnen is a consultant for scientific questions to Bausch & Lomb, Inc. None of the authors has a financial or proprietary interest in any instrumentation or device used in the study.

[Journal of Cataract & Refractive Surgery](#)
Volume 30, Issue 8 , August 2004, Pages 1636-1641

This Document


- [SummaryPlus](#)
- ▶ [Full Text + Links](#)
 - [Full Size Images](#)
- [PDF \(258 K\)](#)

External Links

- 

Actions

- [Cited By](#)
- [Save as Citation Alert](#)
- [E-mail Article](#)
- [Export Citation](#)

[Home](#) [Search](#) [Journals](#) [Books](#) [Abstract Databases](#) [My Profile](#) [Alerts](#)  [Help](#)

[Feedback](#) | [Terms & Conditions](#) | [Privacy Policy](#)

Copyright © 2004 [Elsevier B.V.](#) All rights reserved. ScienceDirect® is a registered trademark of Elsevier B.V.